

ORARISK® HSV Sample Report

Sample, Report

Date of Birth: 09/20/1980 (42 yrs)
Gender: Male
Patient ID: 920-G
Patient Location: Test Site A

Ordering Provider

Ronald McGlennen MD
 7400 Flying Cloud Drive
 Suite 150
 Eden Prairie, MN 55344
 855-672-5362

Specimen#: 5989009003

Accession#: 202306-03363

Specimen: Oral Rinse(P)

Collected: 06/05/2023

Received: 06/06/2023 14:29

Reported: 06/07/2023 09:20

Reason for Testing Evaluation of suspicious lesion
Related Info Not Provided

Lesion Size 2mm x 1mm
Color Mixed
Lesion Location(s) Hard Palate


MOLECULAR DETECTION OF HERPES SIMPLEX VIRUS (HSV) TYPES 1 AND 2 IN THE OROPHARYNX

Test Results

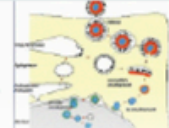
HSV Type 1	Positive
HSV Type 2	Positive

Infection with Herpes Simplex Viruses Types 1 and 2

Structure of the Herpes Simplex Virus



Lifecycle of the Herpes Simplex Virus



Report Includes:



HSV infections are very common, yet can often be mistaken for other causes of oral vesicles, ulcers, and other forms of painful oral and pharyngeal lesions.

Cover

Results & Interpretation

Considerations & Methodology

Learn More at
OralDNA.com

